

Acute Scrotum – When Ultrasound is Enough for the Diagnosis

Carolina Cairrão Padilha*, Lara Delgado

Department of Radiology, Centro Hospitalar de Lisboa Ocidental, Lisbon, Portugal

SECTION 1 – QUIZ

Case

A 45-year-old male presented in the emergency department with a progressive 5 days of pain, in the right testicle. The examination showed a fever (38°C), an increase of the right testicle volume, and pain through palpation. Ultrasound (US) was performed, and what is your diagnosis? [Figures 1-3].

Declaration of patient consent

The authors certify that they have obtained all appropriate patient consent forms. In the form, the patient has given his consent for his images and other clinical information to be reported in the journal. The patient understands that his name and initials will not be published and due efforts will be made to conceal the identity, but anonymity cannot be guaranteed.

Financial support and sponsorship

Nil.

Conflicts of interest

There are no conflicts of interest.

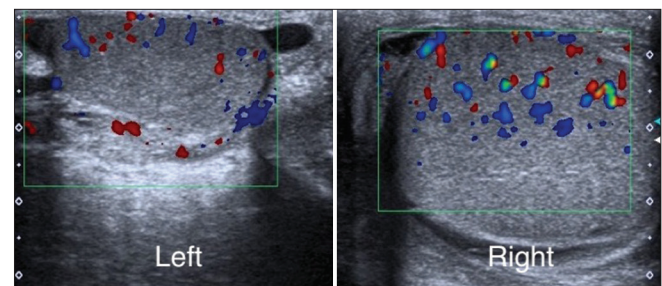


Figure 2: Color Doppler ultrasound in the longitudinal plane of both testicles

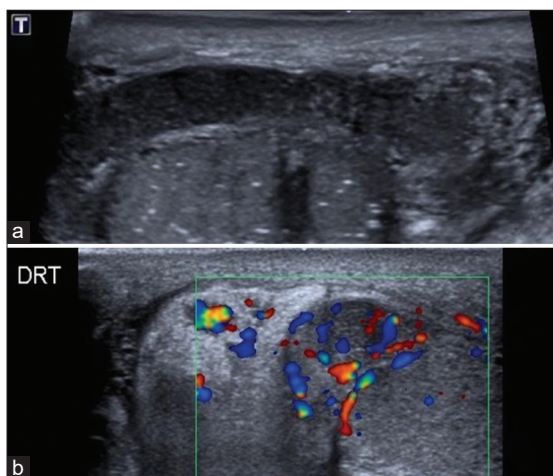


Figure 1: Gray-scale ultrasound of the right epididymis (a), and color Doppler (b) of the right epididymal head and spermatic cord, in the longitudinal plane

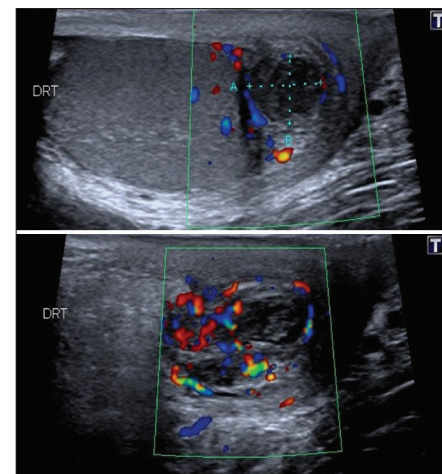


Figure 3: Color Doppler ultrasound in the longitudinal plane of the right epididymal tail

Received: 23-01-2022 Revised: 07-02-2022 Accepted: 01-03-2022 Available Online: 27-05-2022

Access this article online

Quick Response Code:



Website:
<https://journals.lww.com/jmut>

DOI:
10.4103/jmu.jmu_11_22

Address for correspondence:

Dr. Carolina Cairrão Padilha,
Department of Radiology, Centro Hospitalar de Lisboa Ocidental, Hospital
São Francisco Xavier, Estrada Forte Do Alto Duque, 1449-005, Lisbon,
Portugal.

E-mail: carolinacairraopadilha@gmail.com

This is an open access journal, and articles are distributed under the terms of the Creative Commons Attribution-NonCommercial-ShareAlike 4.0 License, which allows others to remix, tweak, and build upon the work non-commercially, as long as appropriate credit is given and the new creations are licensed under the identical terms.

For reprints contact: WKHLRPMedknow_reprints@wolterskluwer.com

How to cite this article: Padilha CC, Delgado L. Acute scrotum – When ultrasound is enough for the diagnosis. J Med Ultrasound 2023;31:348.